

THE WUSV WORKING GROUP - GB



SV – HIP, ELBOW, BACK & DNA SCHEME

All GSD owners in the UK can submit Hip, Elbow and Back x-rays and DNA samples to the German SV (German Shepherd Dog World Governing Body) for results to be recorded in their global database. These results have international recognition.

With recent discussion around the WUSV (World Union Of GSD clubs) Harmonisation Programme for the future, we are getting increased interest and enquiries regarding the SV HD/ED/LUW/DNA Scheme in the UK. As the newly appointed Registrar for this scheme, I have put some information together, which hopefully explains how it works and answers some of the questions people have.

This scheme is overseen in the UK by the WUSV Working Group - GB (BAGSD & GSDL) and administered on their behalf by myself as the Registrar.

FAQ.

Q. What is the SV Scheme?

The scheme is the SV equivalent of the BVA/KC Hip and Elbow Scheme. It offers assessment of Hips, Elbows, LUW and OCD and DNA testing for identification purposes.

Q. Is this scheme available in the UK?

Yes absolutely, there are an increasing number of vets now extremely competent in submitting x-ray plates and DNA to the SV for assessment. The list is available to anyone. However, **any** vet willing to do them for the first time, can do so. All we ask is that they have a quick chat with the WUSV Working Group - GB consultant vet, Mike Guiliard, In advance of the appointment, so they are fully aware of requirements in terms of positioning of x-rays and paperwork and if submitting digital x-rays that they register with the scheme, an easy process for them.

Mr Mike Guiliard MA BetMB CertSAO MRCV

Cheshire Pet (Sandbach) CW11 4RW

Contact – 07784 202024 or office 07784 202026

Q. What is the cost to do this in the UK?

The cost of taking the xrays and dna sample are a matter for you and your selected vet. However, the SV fees that are paid direct from the WUSV Working Group - GB are as follows. We have recently reviewed these in an effort to maintain the low costs where possible. The revised costs valid from 1st August 2017.

HD – £45

ED - £45

OCD – £30

HD with LÜW together – £60

LÜW separately (If HD already evaluated) – £25

DNA – £70

If all x-rays are to be submitted digitally by the vet, then a reduction of 10% will be applied to the X-ray payment.

Example: HD/ED/DNA total payment to WUSV Working Group - GB would be £160. However, if submitted digitally, would be less 10% from HD/ED therefore payment would be £149.

Q. What is LÜW and OCD?

LÜW relates to Lumbar-Sacral Transitional Vertebrae. In absolute layman's terms it is not entirely dissimilar to what we know as Caudia Equine Syndrome. See attached article.

OCD is Osteochondrose – orthopaedic disease of the hip joint.

These X-ray procedures are on a voluntary basis currently but may at some point in the future become mandatory.

Q. I want to go ahead and get my dog assessed under this scheme, what do I do next?

Please follow the below step by step guide below and feel free to message or call me for any advice or guidance at any time on any stage of this process. I am only too happy to help in any way.

WUSV Working Group – GB

Registrar

Heather Macdonald

Conbhairean@btinternet.com or 07876 210243

STEP BY STEP GUIDE

1. Ensure you have 5 generation Kennel Club* pedigree for your German Shepherd Dog – Ensure correct ownership on pedigree (Must be official pedigree – not homemade)
* Note that a KC pedigree is required for dogs born in the UK, for dogs born in other countries the pedigree must be from the registration authority of the country of birth.
2. Ensure you are a member of BAGSD/GSDL/SV
3. Contact registrar, in plenty of time, to order SV paperwork and arrange to make payment to the WUSV Working Group – GB. Paperwork will be sent once payment has been confirmed.
 - 3.1. Registrar: Heather Macdonald
Conbhairean@btinternet.com or 07876 210243
4. Once paperwork received, make appointment with suitable Vet
5. If new process to vet, ensure they contact Mike Guiliard for guidance in advance of appointment – **THIS IS VERY IMPORTANT.**
6. Ensure you have all original paperwork for dog, as well as a copy of original official pedigree, to attend vet with dog for x-rays
7. Take x-rays and complete all paperwork VERY carefully, ensure forms are signed and stamped by vet and signed by owner
8. Ensure DNA sample ONLY with accompanying SV form and copy of pedigree are sent to Heidelberg **same day. Do not send x-rays!**

9. Ensure X-rays and accompanying SV forms, along with original 5 generation pedigree are suitably packaged and sent immediately to the registrar (Heather Macdonald)

9.1. If X-rays are being submitted digitally by your vet ask them to confirm to you the date of submission and the submission reference number. You must still send the SV accompanying forms to the registrar (Heather MacDonald)

10. The registrar will ensure paperwork is correctly completed and stamp pedigree before submitting to SV for scoring.

11. Await results, which can take some weeks. We aim to have results within 4 weeks from submission of forms to SV. Any questions or queries regarding results must be directed through the registrar (Heather MacDonald).

Information for SV-Veterinarians

LUMBAR-SACRAL TRANSITIONAL VERTEBRAE / LTV

Transitional Vertebrae develop at the transition of the vertebral spine segments (e.g. lumbar spine / sacral bone). If this occurs the deformed vertebra shows characteristics of the front segment and of the past segment as well.

The lumbar spine of dogs normally consists of seven vertebrae (L). Three vertebrae (S), which are totally fused at an age of 18 month at latest are forming the sacral bone (Figure 1). Between L7 and S1 exists a normal disc and there is no contact between the transverse processes an no contact to the alia of the ilium (Figure 3). Lumbar-sacral transitional vertebrae (LTV) develop in the region of L7 and S1. They are characterized by an abnormal form most frequently at the spinal and transvers processes. In an advanced stage the vertebral body can also be involved.

A correlation between LTV and the prevalence of Cauda Equina Syndrome (CES) is discussed.

Proposed by the Swiss Dysplasia Commission for the screening on hip radiographs LTV are divided in four types. The differentiation is based on two criteria:

1. Degree of the fusion of the spinal processes of the sacrum
2. Symmetric or asymmetric formation of the transverse processes and configuration of the contact area of transverse processes with the alia of the ilium.

Figure 3 demonstrates a normal lumbar-sacral conjunction (Type 0) on a pelvic radiograph.

Type 1 shows a normal anatomical form of L7 and sacrum bone but with an separated spinal process of S 1 (Figure 4). Type 2 includes all the different forms of LTV with more obvious abnormal anatomical findings if the development is symmetrically (Figure 5).

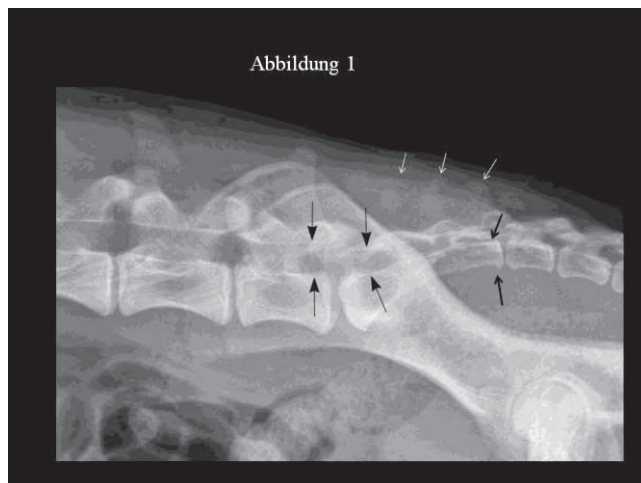
All asymmetrical forms of LTV are included in Type 3 (Figure 6).

A very high risk for the dog to get a cauda equina syndrome (CES) is the development of an OCD (Osteochondrosis dissecans) at S1 (Figure 2). In such cases the disc between L7 and S1 is always damaged.

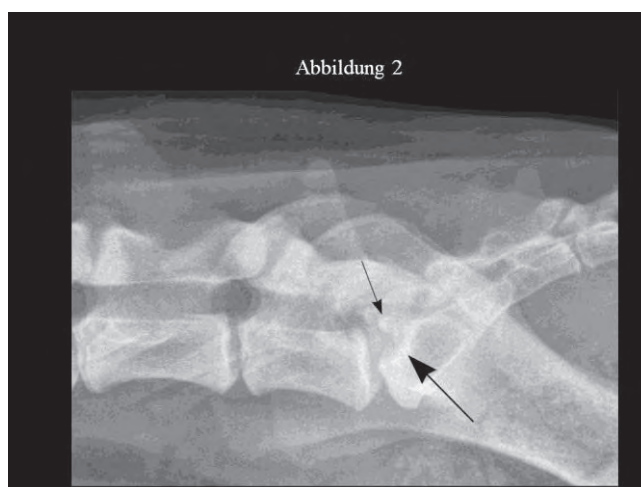
Actually the Verein für Deutsche Schäferhunde (SV) e.V. has decided to include the anatomical changes at the lumbar sacral conjunction, especially LTV and OCD in the screening, but on a voluntary base. To examine LTV the standard pelvis radiograph for CHD is adequate. Except for the identification of a dog on different radiographs also for this examination it is very important that the total pelvis including L7 is displayed on the image (Figure 3). All CHD radiographs, which don't meet this requirement, are not evaluable and have to be refused in any case.

If a dog owner wants to have an examination concerning OCD an additional radiograph has to be made. The image has to demonstrate the region from L 4/5 to the first coccygeal vertebra on a latero-lateral view. The lumbar sacral conjunction has to be in the central beam, no axial rotation of vertebral column and pelvis and the technical quality (detail, contrast) must allow a detailed analysis of the bone structure (Figure 1).

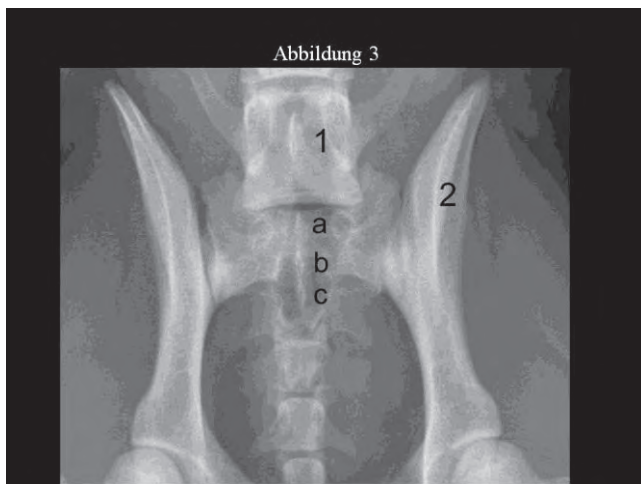
Dr. Bernd Tellhelm



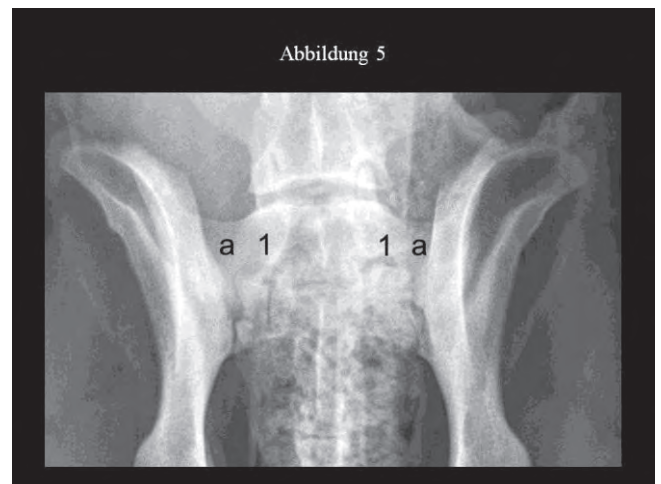
Latero-lateral radiograph of a normal lumbar-sacral conjunction. The bony structures are well defined, the vertebral canal is wide (large black arrows). The three sacral vertebrae (caudal large black arrows to small black arrows) are totally fused and also the spinal processes (white arrows).



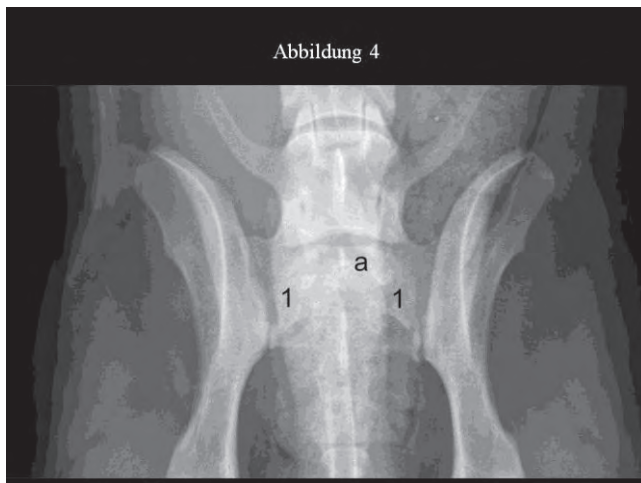Latero-lateral radiograph of the lumbar-sacral conjunction of a dog 12 month of age with an OCD of the first sacral vertebra. The ossification of the front part of the sacral bone is incomplete (large arrow), a separate piece of bone (small arrow) is situated within the vertebral canal.



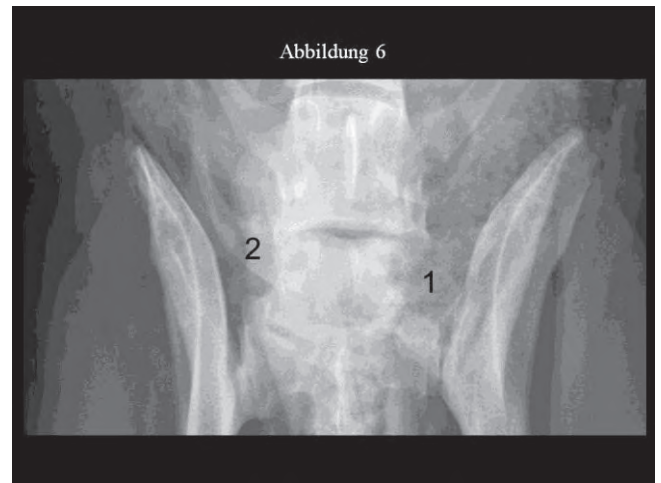Hip-radiograph including the lumbar-sacral region. It shows a normal lumbar-sacral junction (Type 0). The transverse processes of the last lumbar vertebra / L7 (1) are symmetric with a normal orientation (cranio-lateral). There is no contact with the alia of the ilium (2). Sacral bone and L 7 are totally separated. The spinal processes of the sacral bone are fused (a, b, c).



Hip-radiograph including the lumbar sacral region. Demonstrated is a symmetric LTV (1) developing a broad contact area with the alia of the ilium by its transverse processes (a / Type 2).



Hip-radiograph including the lumbar-sacral region. The spinal process (a) of the first sacral vertebra is separated. Symmetric LTV type 1 (1).



Hip-radiograph including the lumbar sacral region. Demonstrated is an obviously asymmetric developed LTV (Type 3). The left transverse process (1) of the vertebra has a broad contact area with the left alia of the ilium. The right transverse process (2) shows a normal configuration.